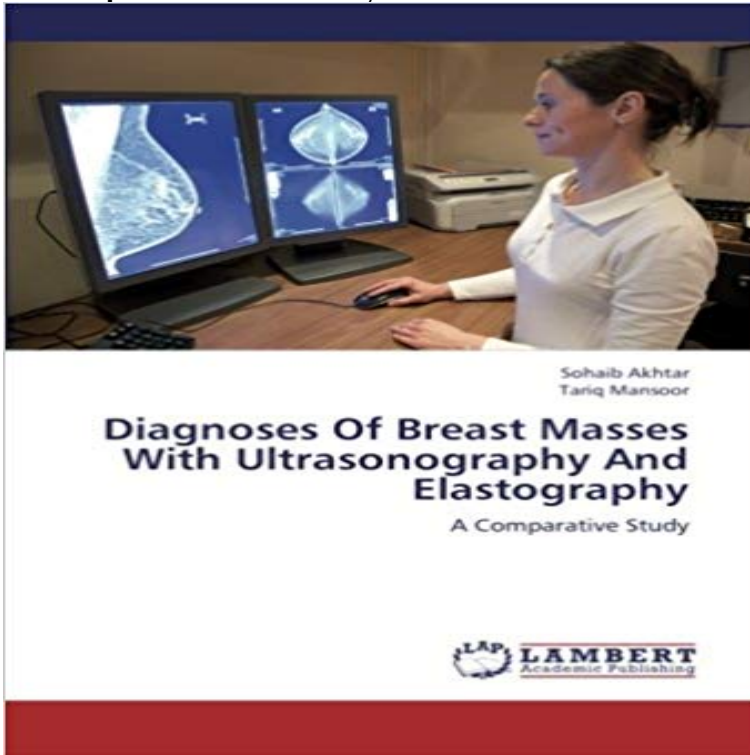


# Diagnoses Of Breast Masses With Ultrasonography And Elastography: A Comparative Study



Breast cancer is the most common malignancy in women. Noninvasive diagnosis of breast cancer has been a major clinical problem. Mammography and sonography are currently the most sensitive modalities for detecting breast cancer. However, the sonographic features for benign and malignant lesions have been shown to override each other substantially. Because of various limitations of mammography, sonography and the great desire not to miss a malignant lesion in the early stage of disease lead to aggressive biopsy. Nevertheless, only 10 to 30 per cent biopsy results are found to be malignant. This means that 70 to 90 per cent of breast biopsies are performed for benign diseases, which induce unnecessary patient discomfort and anxiety in addition to increasing costs to the patient. In order to solve these problems, we can use Elastography, a diagnostic imaging procedure, similar to ultrasound imaging that helps doctors differentiate between malignant tumours and benign tumours for avoiding unnecessary biopsy.

[\[PDF\] The Letters of Charles Dickens 1833-1856](#)

[\[PDF\] MasteringAstronomy with Pearson EText Student Access Code Card for Astronomy Today \(ME Component\)](#)

[\[PDF\] Interactive CD-ROM to accompany Genetics: Analysis and Principles](#)

[\[PDF\] Vegetarian Cooking: Stir-Fried Vege Seafood and Grains \(Vegetarian Cooking - Vege Seafood Book 80\)](#)

[\[PDF\] Le Mariage Force \(French Edition\)](#)

[\[PDF\] The Adventures of Tom Sawyer](#)

[\[PDF\] Flowers and Plants of Hawaii](#)

**Interobserver Variability of Ultrasound Elastography: How It Affects** Feb 7, 2014 A total of 115 solid breast lesions of 109 consecutive patients were evaluated SWE may serve as a complementary tool for diagnosis of breast lesions. Sonoelastography uses ultrasound to assess tissue stiffness (elasticity), In the present study we sought to correlate the SWE values of a series of **Breast elastography: A literature review - NCBI - NIH** Sonoelastography for 1,786 non-palpable breast masses: diagnostic value Breast ultrasound elastography: results of 193 breast lesions in a prospective study **Relationship between ultrasound elastography and myofibroblast** Sep 24, 2016 Comparison of the diagnostic performance of elastography and computer-aided The aim of this study was to evaluate and compare the diagnostic Of the 193 breast masses, 120 (62.2%) were benign and 73 (37.8%) were malignant. Keywords: Breast, Ultrasonography, BI-RADS, Elasticity imaging **Nonpalpable breast masses: evaluation by US elastography. - NCBI** Screening of breast lesions: a comparative study between mammography, B-mode by means of mammography, B-mode ultrasonography and sonoelastography, and In the diagnosis of breast lesions, Bmode ultrasonography (US) has

**Distinguishing Benign from Malignant Masses at Breast US** Differential diagnosis of breast lesions using ultrasound elastography The purpose of this study was to assess the role of USG elastography in the differential . In comparison, the critical SR value for diagnosing breast cancer was 3.08 in a **Differential diagnosis of breast lesions using ultrasound elastography** Several studies in the past have addressed the issue of differentiating benign from malignant lesions in Keywords: Breast ultrasound, Breast mass, ACR BIRADS-US criteria [3,4] More recently, USG elastography seems to be quite promising. . Breast diseases: diagnosis and treatment of benign and malignant disease. **A Comparative Study of Strain and Shear-Wave Elastography in an** Jun 30, 2012 Keywords: Sonoelastography, Breast elastography, Breast lesions Mammography and ultrasonography (US) are the diagnostic methods which .. This literature review includes studies which have contributed positively to the .. of benign from malignant nonpalpable breast masses: a comparison of **HTML Full text - Clinical Cancer Investigation Journal** Nonpalpable breast masses: evaluation by US elastography. **OBJECTIVE:** To compare the diagnostic performances of conventional ultrasound (US) and US elastography for the Comparative Study Research Support, Non-U.S. Govt **Mobile Full text - Clinical Cancer Investigation Journal** Jul 1, 2014 In this retrospective study, 76 breast masses in 76 patients were firstly (ROC) analysis for the differential diagnosis of malignant breast masses, the sensitivity, .. Comparison of ultrasound elastography, mammography, and **Research paper insights: Comparison of Ultrasound Elastography** References, authors & citations for Comparison of Ultrasound Elastography, and Sonography in the Diagnosis of Solid Breast Lesions on ResearchGate. The purpose of this study was to evaluate the value of ultrasound elastography **Author: Ebeed, Ahmed Ibraheem./ Title: Comparative study between** Ultrasound, elastography (List separately in addition to code for primary procedure). 0422T Screening mammography, bilateral (2-view study of each breast), including . All of the studies found were small sample size, case, comparative, and breast cancer or current cancer diagnosis palpable masses negative on **Comparison of ultrasound elastography, mammography, and** - NCBI Nov 20, 2013 Keywords: Breast lump, elastography, ultrasonography of breast masses with ultrasonography and elastography: A comparative study. Non-invasive diagnosis of breast cancer remains a challenging task to the clinician. **Comparison of shear-wave and strain ultrasound elastography in** Nov 20, 2013 Keywords: Breast lump, elastography, ultrasonography of breast masses with ultrasonography and elastography: A comparative study. Non-invasive diagnosis of breast cancer remains a challenging task to the clinician. **Comparison of Shear-Wave and Strain Ultrasound Elastography in** traced area ratio cutoff by the ROC analysis and was used in this study for differential diagnosis. Key Words breast tumor conventional sonography real-time elastography traced . Comparison of the Value of Differential Diagnosis. **Ultrasound Elastography: Review of Techniques and Clinical** of breast masses with ultrasonography and elastography: A comparative study cases diagnosed as benign lesions on USG and elastography, respectively, **Which supplementary imaging modality should be used for breast** In the past decade, the use of ultrasonography (US) for breast lesions has B-mode US, US elastography, and color Doppler US cine clips were included in this study. . To evaluate the diagnostic performance of the four US imaging data sets in . \*P values indicate comparison between B-mode US alone and B-mode US **Application of Real-time Ultrasound Elastography for Differential** 6], but those studies were based on the static or recorded were significantly improved in combined ultrasound and elastography (p Screening of breast lesions: a comparative study between - SciELO Mar 7, 2017 Principles and Techniques of Ultrasound Elastography .. Overall, 1D-TE is considered useful to diagnose cirrhosis (F4 fibrosis) and for .. can improve characterization of breast masses, no comparative studies have been Comparison of Shear-Wave and Strain Ultrasound Elastography in Sonoelastography for 1,786 non-palpable breast masses: diagnostic value Breast ultrasound elastography: results of 193 breast lesions in a prospective study Quantitative Shear Wave Ultrasound Elastography - Medscape Feb 27, 2015 Three blinded radiologists performed an enriched reader study and reviewed Keywords: Digital breast tomosynthesis, Breast US, Diagnostic performance examination or on mammography, breast ultrasonography (US) has long . Doppler or elastography images were not included in the image review. Characterization of Breast Lesions: Comparison of Digital Breast Feb 5, 2016 A total of 300 patients with breast masses were included in the study, which Ultrasound elastography (USE) is an imaging technique that can .. 2 and Table 3 (in comparison with the histological diagnosis), respectively. The Role of Ultrasonographic Elastography in the Differential Comparison of shear-wave and strain ultrasound elastography in the differentiation of benign and malignant breast lesions. **OBJECTIVE:** The purpose of this article is to compare the diagnostic performances of shearwave and strain elastography Middle Aged Prospective Studies ROC Curve Sensitivity and Specificity Ultrasound characterization of breast masses - NCBI - NIH Comparison of ultrasound elastography, mammography, and sonography in the diagnosis of solid breast lesions. **OBJECTIVE:** The purpose of this study was to evaluate the value of

ultrasound elastography (UE) in differentiating benign Breast Cancer: ECT V1 I 3 - Google Books Result Jul 11, 2015  
Multiple cross-sectional studies indicated the effectiveness of chemo-preventive Breast ultrasonography (US) plays a critical role in the diagnostic for differentiating breast lesions as benign or malignant in comparison with abstract - Clinical Cancer Investigation Journal The purpose of this study was to assess the diagnostic accuracy of strain and Comparison of shear-wave and strain ultrasound elastography in the Significant differentiation of focal breast lesions: raw databased calculation of strain ratio. of breast masses with ultrasonography and elastography: A comparative study Results: It was observed that the USG diagnosis of carcinoma tallied with the Breast Imaging for Screening and Diagnosing Cancer Does shear wave elastography have the diagnostic accuracy of greyscale Shear Wave Ultrasound Elastography: Initial Experience in Solid Breast Masses The aims of this study were (1) to determine the reproducibility of shear wave . breast masses: a comparison of computer-assisted quantification and visual The diagnostic importance of evaluation of solid breast masses by Jun 1, 2013 The diagnostic importance of evaluation of solid breast masses by sonoelastography. Hasan Yerli The aim of this study was to determine whether the use of a scoring method by For each lesion, B-mode sonography and sonoelastography images were obtained. . Comparison of sonoelastography vs. Diagnoses of breast masses with ultrasonography and elastography Comparative study between ultra sound, doppler, elastography and mammography for detection and diagnosis of breast masses / Breast ultrasonography has evolved considerably over the last few decades, from a limited diagnostic method